

# Stapler Laryngectomy

Bipin T Varghese

## ABSTRACT

Closed stapling of the pharynx after careful separation of the laryngeal frame work from the adjacent pharynx is a viable option in total laryngectomy for endolaryngeal cancers. Author describes his experience and improvisation that ensures success in stapler laryngectomy.

**Keywords:** Closed stapling, Total laryngectomy, Technique.

**How to cite this article:** Varghese BT. Stapler Laryngectomy. *Int J Phonosurg Laryngol* 2013;3(1):10-11.

**Source of support:** Nil

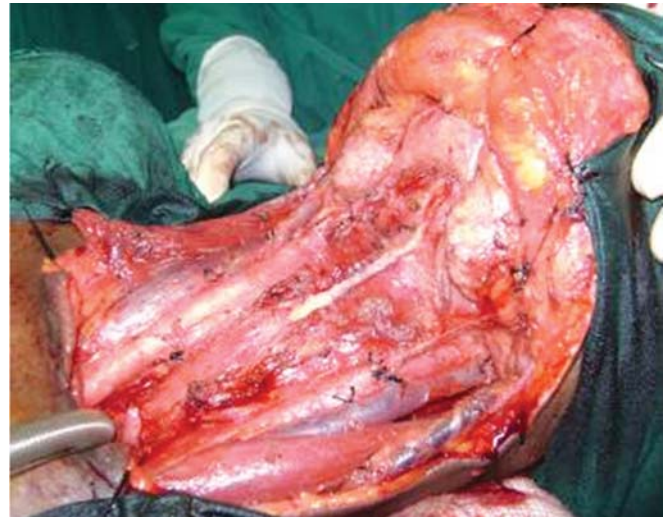**Conflict of interest:** None declared

## INTRODUCTION

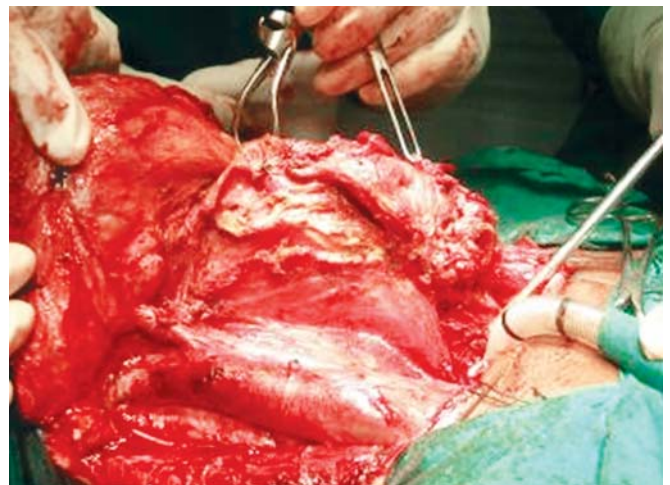
Closed stapling after laryngectomy saves operating time and provides a watertight uncontaminated closure as good as a meticulous straightline suturing of the neopharynx (Fig. 1).<sup>1,2</sup> We at the Regional Cancer Centre, Thiruvananthapuram, have been using no.60 linear stapler (Ethicon) since September 2004 and on a personal basis I have done more than 50 cases.

The technique is easy and quick to learn and the only difficulty is prevention of epiglottic entanglement in the stapling device which can predispose to a fistula. For the initial four cases I have achieved this by catching and pulling down the epiglottis blindly with an Allis forceps introduced through the lower end of trachea. However, this was found to be cumbersome owing to the difficulty in holding on to the epiglottis. Hence, for the next 12 cases I have modified this by using the long ends of an epiglottic suture placed with the help of Macintosh laryngoscope immediately after the intubation. With the help of a long curved artery forceps (Roberts forceps), this suture is pulled from the tracheal cut end with the assistance of a rigid direct laryngoscope. The retracted epiglottis can either be held away from the stapler line by an assistant or sutured to the tracheal end in a self-retaining manner. Since this is time consuming, most recently I have resorted to the Cricoid hook retraction technique to segregate the epiglottis from stapler line (Fig. 2). This is described below.

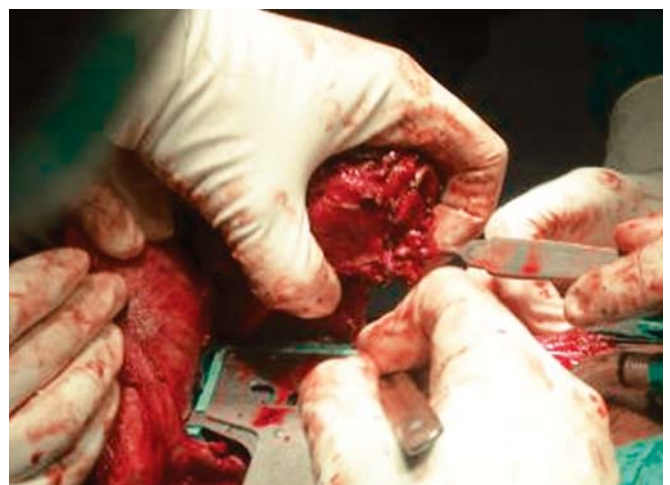Standard steps of laryngectomy are carried out and the larynx is skeletonized taking care not to open the pharynx. Superiorly, the suprahyoid muscles are severed till the mucosa of the vallecula exposing the hyoid bone and the thyroid cartilage. It is advised to preserve the thyrohyoid ligament, which will help in easier application of the stapler by preventing entrapment of the hyoid in the stapler line.



**Fig. 1:** Straight line closure achieved with a linear no. 60 stapler



**Fig. 2:** Separation of the laryngeal framework before application of the stapler



**Fig. 3:** The cricoid hook retraction of epiglottis during stapling

The trachea is now transected at the required level, so that an adequate inferior margin is attained visualizing any subglottic extent of the tumor. The trachea is now separated meticulously from the esophagus from below upward till the entire laryngotracheal framework is separated from the pharyngoesophageal mucosa (Fig. 2). A cricoid hook is inserted through the tracheal lumen into the larynx to retract the epiglottis so that it does not get caught within the jaws of the stapler. Epiglottis can be palpated at the suprahyoid region and is pushed downward to enable the catch. Now the linear stapler is applied between the larynx and the pharynx taking care that no other soft tissue, the greater horn of hyoid or the ala of thyroid cartilage gets caught within the jaws of the stapler line (Fig. 3). The stapler is then fired and the laryngeal specimen is separated from rim of stapler jaws by a scalpel. Primary tracheoesophageal puncture (TEP) can be made with care after application of the stapler with the help of an esophagoscope introduced through the as in case of a secondary TEP.

Feeding tube (Ryles tube) is now introduced. If the feeding tube was in place before the surgery, it may be removed before application of the stapler and reintroduced after the procedure to prevent it from getting entangled in the stapling line.

In none of the cases was a second stapler needed for complete closure. We have not fed our patients by mouth till the 8th postoperative day. In all the post-irradiated cases oral feeding was commenced only on the 10th day. On an interim analysis after my 28th case it was observed that

prolonged Ryles tube feeds were required for five patients who developed postoperative leaks. Eight patients had tracheoesophageal (TE) voice restorations five of whom had primary TEP and three had secondary TEP. The primary TEP was performed with the help of a rigid hypopharyngoscope as in a secondary puncture. All patients had good voice.

## CONCLUSION

Closed stapler closure is a reliable alternative to suturing when the cancer is endolaryngeal. Good case selection, preoperative skeletonization and separation of the laryngeal framework (Figs 2 and 3) from the remnant pharynx and proper application of the stapling device without catching any rigid structures on the laryngeal framework are the key factors that ensure success with this technique.

## REFERENCES

1. Bedrin L, Ginsburg G, Horowitz Z, Talmi YP. 25-year experience of using a linear stapler in laryngectomy. *Head Neck* 2005;27:1073-79.
2. Talmi YP, Finkelstein Y, Gal R, Shvilli Y, Sădov R, Zohar Y. Use of a linear stapler for postlaryngectomy pharyngeal repair: A preliminary report. *Laryngoscope* 1990;100:552-55.

## ABOUT THE AUTHOR

### Bipin T Varghese

Additional Professor, Department of Surgical Oncology (Head and Neck Services), Regional Cancer Centre, Thiruvananthapuram, Kerala India, e-mail: bipintv@gmail.com