

Deep Neck Infections: Continuing Burden in Developing World

Kanika Rana, Praveen Kumar Rathore, Vikram Wadhwa, Surinder Kumar

ABSTRACT

Deep neck infections (DNIs) continue to burden the health care system in developing countries like India. Aim of our study was to determine clinical features, diagnostic and therapeutic aspects of DNIs, various microorganisms involved in DNIs and their antibiotic sensitivity and to study the outcome of described treatment response. Fifty patients with DNIs were managed at the department of ENT in our hospital from September 2009 to September 2010. There were 29 male (58%) and 21 female (42%) patients with age ranging from 6 months to 75 years. Maximum patients presented in emergency department with complain of neck swelling and pain. Most common abscess encountered was of submandibular region. Odontogenic cause was found to be the most common cause of DNIs. Surgical intervention was required in 39 patients. No major complications were seen. It was observed that the low socioeconomic status along with illiteracy and lack of adequate management of early infection at primary health care level lead to prevalence of these infections in developing countries like ours.

Keywords: Deep neck infections, Odontogenic, Socioeconomic status.

How to cite this article: Rana K, Rathore PK, Wadhwa V, Kumar S. Deep Neck Infections: Continuing Burden in Developing World. *Int J Phonosurg Laryngol* 2013;3(1):6-9.

Source of support: Nil

Conflict of interest: None declared

INTRODUCTION

Though with the use of newer antibiotics and timely surgical intervention complications of deep neck infections (DNIs) have been drastically reduced, but a large number of cases still continue to burden our health care infrastructure. The important reasons being, illiteracy, unhygienic living, late presentation and poor management at primary health care level. Early and aggressive management is required so that huge deep neck abscesses (DNAs) do not form and life threatening complications like descending mediastinitis, septic shock, upper airway obstruction, jugular vein thrombosis, etc. are prevented.

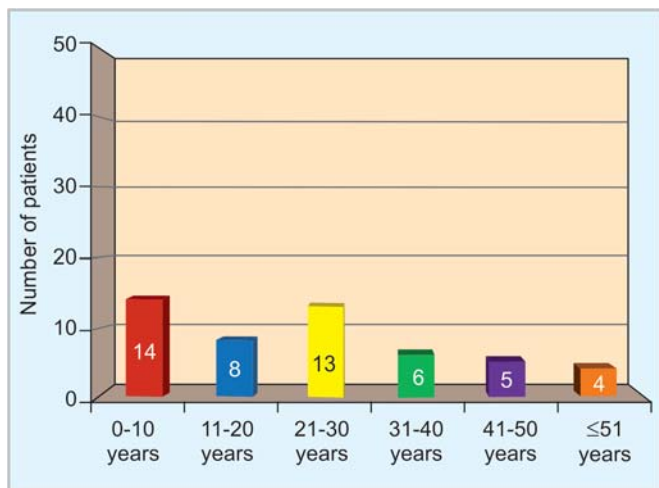
MATERIALS AND METHODS

Our study group of 50 patients were diagnosed and managed at ENT and Head and Neck Surgery Department of Maulana Azad Medical College and associated Lok Nayak Hospital, New Delhi, from September 2009 to September 2010. Inclusion criteria for the study were patients with swelling in neck with or without fluctuation and associated features

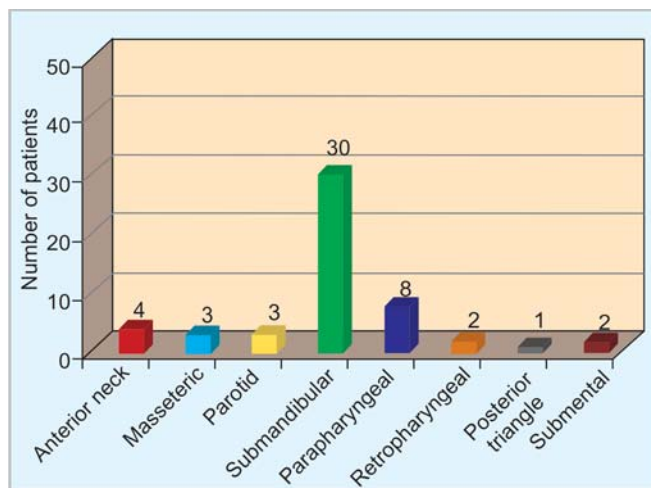
of fever, pain, difficulty swallowing, difficulty breathing or cough and any associated lymphadenopathy. Patients with underlying malignancy, penetrating foreign body, bleeding/coagulation disorders peritonsillar abscess, with prior tracheostomy, penicillin hypersensitivity and with life-threatening presentation requiring urgent surgical management were excluded from the study. Detailed history of every patient was taken and a thorough examination was done. Contrast enhanced computed tomographic scan (CECT) of neck, chest X-ray and all relevant hematological examinations were done. Before starting the treatment, wide bore needle aspiration was done and aspirates were sent for bacteriological and antibiotic sensitivity. All patients were started on injectable crystalline penicillin, gentamicin and metronidazole as per predecided hospital protocol. Supportive therapy in form of intravenous fluids, analgesics, antipyretics, antiemetics, mouthwashes, etc. were given. Patients were kept on conservative management for 2 days and response of the treatment was observed. Treatment was changed in view of antibiotic sensitivity results and clinical responsiveness. Surgical treatment, that is, incision and drainage of abscess was done if patient did not improve with medical management. All patients were kept in hospital for impending complications. After discharge the patients were followed for 2 months.

RESULTS

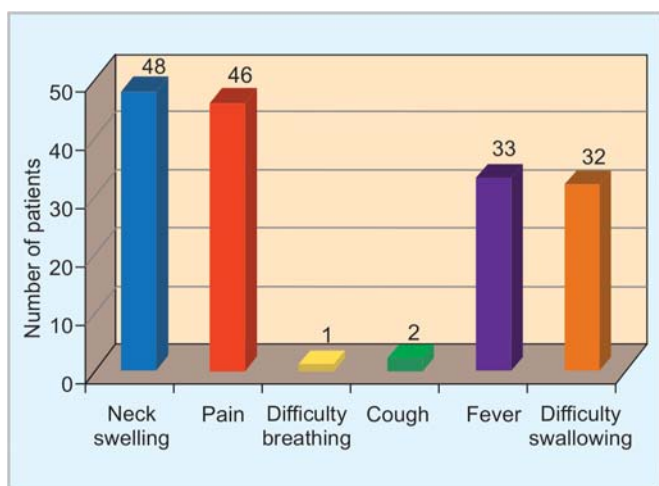
Out of 50 patients, 29 (58%) were males and 21 (42%) were females. The average duration of symptoms after which the patient presented to our hospital was 15 days. Age distribution of patients is given in Graph 1. Maximum patients were of children less than 10 years (28%) in age and second peak was of age group between 30 and 40 years. Socioeconomic status of all the patients was determined using the Kuppuswamy socioeconomic scale.¹ Forty patients (80%) belonged to low socioeconomic strata. 75% of the patients were illiterate and did not understand the predisposing factors, nature of disease and its complications. Poor orodental hygiene with caries was found in 20 patients (40%). Tobacco chewing was the most common addiction seen in 36% patients followed by smoking. Odontogenic source was the most common cause of infection seen in 48% patients. This was followed by tonsillar cause seen in 14% patients. In 20% patient, no definite cause was



Graph 1: Age distribution of patients



Graph 3: Location of abscess



Graph 2: Clinical presentation of patients

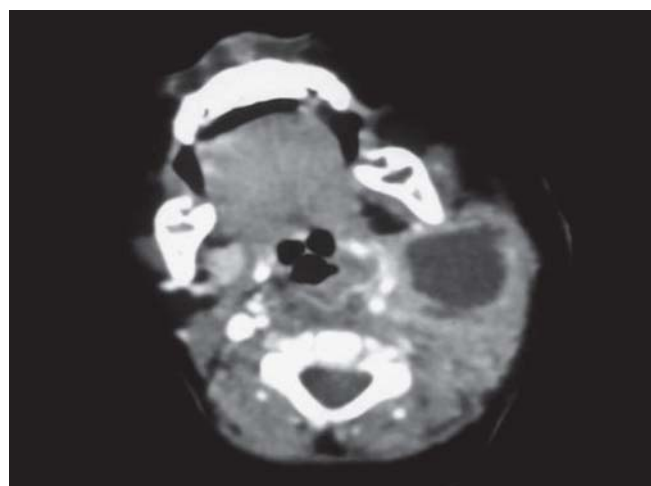


Fig. 1: CECT neck showing parapharyngeal and retropharyngeal abscess

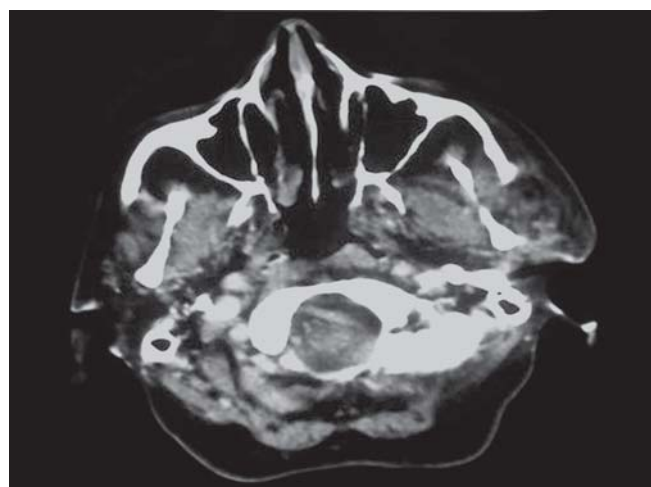


Fig. 2: CECT neck showing parotid abscess

identified. Diabetes was seen in one patient (2%) and coronary artery disease was seen in two patients (4%). Only one patient was HIV positive, while two patients (4%) had tuberculosis.

Neck swelling and pain was the most common complaint which was seen in 48 patients (96%) and 46 patients (92%) respectively. Thirty-three patients (66%) had associated fever and 32 patients (64%) had difficulty in swallowing. Difficulty breathing and cough were less commonly seen in these patients (Graph 2).

Submandibular abscess was the commonest abscess and was seen in 30 patients (60%). It was followed by parapharyngeal abscess seen in 16% patients, parotid abscess in 6% patients, retropharyngeal abscess in 4% patients, submental abscess in 4% patients and posterior triangle abscess in 2% patients as shown in Graph 3. All clinical findings were confirmed using CECT neck (Figs 1 to 3). No patient had any respiratory distress before or during treatment.

Pus was sterile in 33 patients (66%). *Staphylococcus aureus* was isolated in 11 patients (22%), followed by *Streptococcus pyogenes* in four patients (8%) and *E. coli* in two patients (4%).

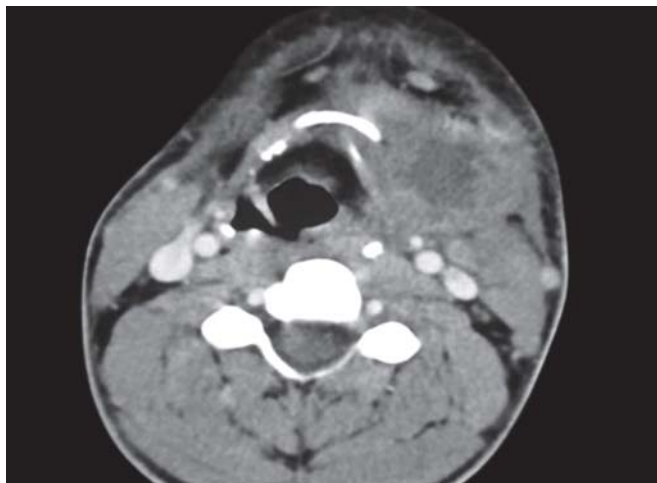

Fig. 3: CECT neck showing submandibular abscess

Incision and drainage was required in 39 patients (78%), while 11 patients were treated with medical management. The antibiotic management was not changed in 40 (80%) patients and these improved with or without surgical intervention. The average length for giving antibiotics was 2 weeks and mean duration of hospital stay was 14 days.

DISCUSSION

In our study, highest percentage of cases belonged to less than 10 years as against the literature available, which had highest presentation in fourth decade.² Also, as per a study by Thompson et al, pediatric population showed a decrease in incidence with increase in age.³ Similar to other studies, pain and neck swelling were the most common symptoms in our study. Though Gidley et al and Mayor et al observed fever and odynophagia are the most common symptoms.^{4,5}

In our study, odontogenic cause was found to be the commonest cause of DNIs seen in 40% patients. Its reported prevalence is 22.7 to 43% and most commonly due to mandibular molar teeth.^{6,7} This is due to poor orodental hygiene, habit of tobacco chewing and delay in taking dental treatments. The submandibular space was the most common site of infection seen in 60% patients, mainly because of dental pathology. Most common microorganism identified in our study was *Staphylococcus aureus* isolated in 11 patients (22%) similar to another study.⁷ This was followed by *Streptococcus pyogenes*, cultured in four patients (8%) and *E. coli*, cultured in two patients (4%).

In our study, only one patient was diabetic, though literature shows prevalence of DNIs in diabetics to be between 16 and 20%. A study by Huang et al suggested that diabetes and the presence of other underlying systemic diseases significantly increase the risk of complications.⁸

All patients had CECT neck and this was helpful to describe extension of infection and precise treatment plan.⁹ The medical management was done with injectable

crystalline penicillin, gentamicin and metronidazole and this was shown to be successful in 40 patients (80%) and no change in treatment was required in these patients. This shows that these drugs are still effective for most cases.

Incision and drainage was required in 39 patients (78%), while 11 patients (22%) were treated with medical management. This was very important here because aggressive and early management prevents spread of DNIs and further formation of huge DNAs with complications. But, a keen observation should be kept and any sign of deterioration or unresponsiveness should be considered as an indication for surgical drainage. None of our patients required a tracheostomy. In cases of Ludwig's angina, edema of the floor of the mouth and its posterior spread might require an emergency tracheostomy.

In our study, we did not see any life-threatening complication. DNAs have propensity to spread along the fascial planes of the neck, and thus can easily be complicated by involvement of vessels and neck organs. The descending necrotizing mediastinitis is the most feared complication and it results from retropharyngeal abscess extension into posterior mediastinum. Complications, like cavernous sinus thrombosis, have been reported in patients with parapharyngeal abscess.¹⁰ Septic shock has been seen and has high mortality. Recurrence, mediastinal spread, bacteremia, suppurative thyroiditis and pulmonary edema have been described in literature.^{11,12} Thrombophlebitis of internal jugular vein and erosion of carotid artery have been described.

The use of computed tomography, early recognition of DNI and DNA, and aggressive treatment are essential for an improved outcome. Better literacy levels and good management at primary health care level will go a long way in reducing this burden of DNI in the developing countries and thereby reduce cost burdens incurred due to their treatment.

CONCLUSION

In spite of the recent advances in diagnosis and advent of newer antibiotics, DNAs still continue to prevail in our society. Though the incidence of complications associated with DNAs has decreased over the last decade still the incidence of these potential life threatening conditions in developing countries mandates that proper attention be given to them.

Early diagnosis, aggressive management with surgical intervention and proper airway management decrease the complications and mortality associated with deep neck abscesses.

Since prevention is better than cure therefore measures should be taken for prevention of these deep neck infections/ abscesses and aggressive treatment should be started in order to prevent any associated complications. As lack of awareness and poor health seeking behavior with low literacy rates are responsible for these cases, measures directed toward these issues should be initiated and continued for the prevention of DNIs.

REFERENCES

1. Kumar N, Shekhar C, Kumar P, et al. Kuppuswamy's socioeconomic status scale-updating for 2007. *Indian J Pediatr* 2007;74:1131-32.
2. Ridder GJ, Technau-Lhling K, Sander A, Boedeker CC. Spectrum and management of deep neck space infections: An 8-year experience of 234 cases. *Otolaryngol Head Neck Surg* 2005;133(5):709-14.
3. Thompson J, Cohen S, Reddix P. Retropharyngeal abscess in children: A retrospective and historical analysis. *Laryngoscope* 1998;98(6):589-92.
4. Gidley P, Ghorayeb B, Stiernberg C. Contemporary management of deep neck space infections. *Otolaryngol Head Neck Surg* 1997;116(1):16-22.
5. Mayor G, Millan J, Martinez-Vidal A. Is conservative treatment of deep neck space infections appropriate? *Head Neck* 2001;23(2):126-33.
6. Agarwal AK, Sethi A, Sethi D. Role of socioeconomic factors in deep neck abscesses: A prospective study of 120 patients. *Br J Oral Maxillofac Surg* 2007;7:553-55.
7. Meher R, Jain A, Sabharwal A. Deep neck abscess: A prospective study of 54 cases. *J Laryngol Otol* 2005Apr; 119:299-302.
8. Huang TT, Liu TC, Chen PR. Deep neck infection: Analysis of 185 cases. *Head Neck* 2004 Oct;26(10):854-60.
9. Boscolo-Rizzo P, Marchiori C, Zanetti F. Conservative management of deep neck abscesses in adults: The importance of CECT findings. *Otolaryngol Head Neck Surg* 2006;135(6): 894-99.
10. Kiddee W, Preechawai P, Hirunpat S. Bilateral septic cavernous sinus thrombosis following the masticator and parapharyngeal space infection from the odontogenic origin: A case report. *J Med Assoc Thai* 2010 Sep;93(9):1107-11.
11. Tan P, Chang L, Huang Y, Chiu C, Wang C, Lin T. Deep neck infections in children. *J Microbiol Immunol Infect* 2001;34: 287-92.
12. Liu CH, Lin CD, Cheng YK. Deep neck infection in children. *Acta Paediatr Taiwan* 2004 Sep-Oct;45(5):263.

ABOUT THE AUTHORS

Kanika Rana (Corresponding Author)

Senior Resident, Department of ENT, Maulana Azad Medical College New Delhi, India, Phone: 9873334274, e-mail: kanika.kanuuu@gmail.com

Praveen Kumar Rathore

Director and Professor, Department of ENT, Maulana Azad Medical College, New Delhi, India

Vikram Wadhwa

Specialist, Department of ENT, Maulana Azad Medical College, New Delhi, India

Surinder Kumar

Director and Professor, Department of Microbiology, Maulana Azad Medical College, New Delhi, India