

Gore-Tex Medialization Thyroplasty in Patients with Unilateral Vocal Cord Paralysis: An Audit of 47 Cases

¹Sanjeev Mohanty, ²M Gopinath, ²Mukundan Subramanian

¹Professor and Senior Consultant, Department of ENT and Head and Neck Surgery, Sri Ramachandra University, Chennai, Tamil Nadu, India

²Assistant Professor, Department of ENT and Head and Neck Surgery, Sri Ramachandra University, Chennai, Tamil Nadu, India

Correspondence: Sanjeev Mohanty, Professor and Senior Consultant, Department of ENT and Head and Neck Surgery Sri Ramachandra University, Chennai-600116, Tamil Nadu, India, Phone: 91-9840131091, e-mail: drsanjeevmohanty@gmail.com

ABSTRACT

Though the surgical technique of medialization thyroplasty has been standardized, still the ideal implant has not been defined in the management of unilateral vocal cord paralysis. The authors present their experience of Gore-tex as the implant material.

Keywords: Medialization thyroplasty, Gore-tex.

INTRODUCTION

Although the ideal implant for medialization thyroplasty has not been defined, there has been increased enthusiasm for the utilization of expanded polytetrafluoroethylene or Gore-Tex as the implant of choice in the treatment of unilateral vocal cord paralysis. The material has many advantages not found in solid implant types, however there is more to Gore-Tex than simply an alternative implant material.¹ Gore-Tex is malleable, adjustable within the cartilaginous window, and requires only a small fenestration. The procedure is reversible and revisable, and the complications are quite limited. When they do occur, they are commonly managed with simple procedures that allow future restoration of vocal cord position and quality of voice.

MATERIALS AND METHODS

A prospective study was conducted between 2004 and 2009 in the Department of ENT, Head and Neck Surgery, Sri Ramachandra University, Chennai, India. All 47 patients with unilateral vocal cord paralysis were selected and subjected to Gore-Tex medialization thyroplasty. All surgeries were done by the principal author.

Exclusion Criteria for the Study

1. Age less than 18 years
2. Malignant disease overlying the laryngotracheal complex
3. Bilateral vocal fold paralysis
4. Abnormal nonparalyzed fold
5. Other disorders affecting the larynx (voice box), such as multiple sclerosis, myasthenia gravis, spasmodic dysphonia, or essential voice tremor
6. Prior surgery to either vocal folds
7. Presence of lesions on the vocal folds
8. Previous or planned irradiation of the voice box.

Technique of Gore-Tex Medialization Thyroplasty

The technique for Gore-Tex thyroplasty has been described in detail by Zeitels.² Essentially, a window is created by electrocautery over the thyroid lamina. The exact size and precise placement of the window is not critical, since the Gore-Tex can be inserted easily into locations that enhance phonatory function by advancing it bluntly with a Freer's elevator (Figs 1 and 2).

The following parameters with respect to voice were noted preoperatively and at the 3rd postoperative month:

Video Laryngoscopy

Because thyroplasty is essentially a mechanical alteration, assessment of glottic gap through videolaryngoscopy is the most direct method of observing the anatomic results of surgery. This procedure was digitally archived and later evaluated by two surgeons not involved in the operative treatment.

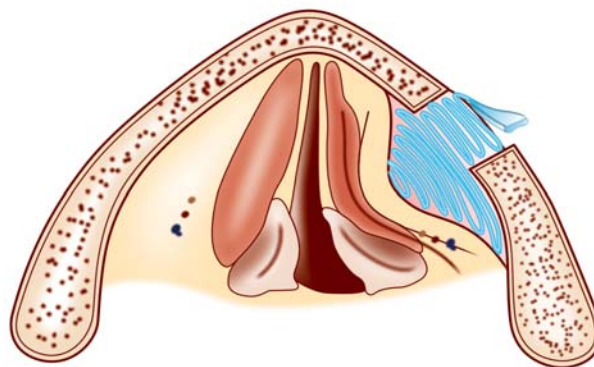


Fig. 1: Thin piece of Gore-Tex is layered into the window (Axial view)

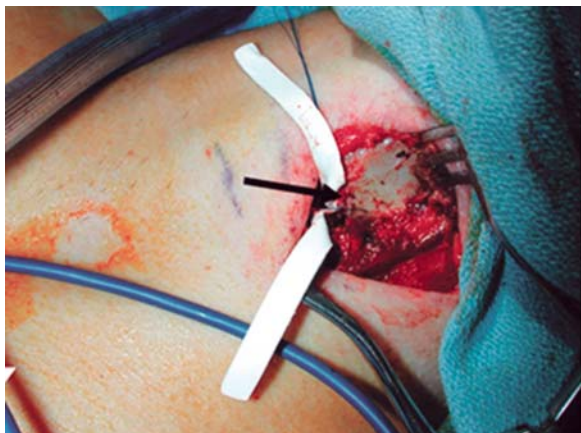

Fig. 2: Folding in Gore-Tex ribbon through the thyroid cartilage window

Maximal Phonation Time

Objective measures of phonatory ability are extremely useful in assessing the results of surgical therapies. The maximum phonation time (MPT) is measured using a stopwatch while the patient sustains the vowel 'a' following deep inspiration.

Patient's Self-Evaluation

Thyroplasty candidates nearly universally present with dysphonia and the benefit of having heard the patient's premorbid voice is rarely conferred upon the physician. Such a qualitative baseline may be a crucial marker in assessing the success or failure of thyroplastic surgery. The authors used a series of questions designed to assess patient satisfaction. The questions were as follows:

1. On a visual analog scale of 1 to 10 with 1 being the same voice previous to the surgery and 10 being their original voice, how would you rate your preoperative versus postoperative voice?
2. With the benefit of hindsight, would you have this surgery again if you had to relive the decision?
3. Did the surgery have an impact on your social or professional life?

RESULTS

47 patients with unilateral vocal cord paralysis were selected and subjected to Gore-Tex medialization thyroplasty from 2004 to 2009. The age of the patients varied from 19 to 72 years with a mean age of 35 years. There were 32 male and 15 female patients. Of these, 42 patients had left vocal fold paralysis and 5 had right vocal fold paralysis. 32 cases were labeled idiopathic after clinical examination, laboratory investigations and radiology revealed no demonstrable cause of the paralysis. 12 cases were following surgical procedures to the chest/neck.

Etiology	Number of cases
Idiopathic	32
Iatrogenic	12
Traumatic	3

One patient is a vocal performing artist and has resumed singing activities almost to her original capability.

One patient developed respiratory distress on the evening of the day of surgery due to excessive medialization which necessitated removal of the implant and needed a temporary tracheostomy. Another patient (post-traumatic) developed graft extrusion on the 2nd week following surgery. The Gore-Tex was removed and surprisingly there was no vocal deterioration. This could be attributed to the inflammatory response which functioned as a tissue expander.

Video Laryngoscopy

Postoperatively 45 out of 47 patients had complete glottal closure. Two patients had a partial glottal closure (who developed postoperative complications).

Maximal Phonation Time

MPT increased in all cases postoperatively from an average value of 3.94 to 17.02 seconds postoperatively.

Patient's Self-Evaluation

On a visual analog scale of 1 to 10 with 1 being the same voice previous to the surgery and 10 being their original voice the following were noted:

VAS	No. of patients
10	15
9	16
8	11
7	1
6	1
5	1
1-4	2

All 47 patients agreed they would have this surgery again if they had to relive the decision. The patient who underwent tracheostomy following the surgery underwent revision Gore-Tex implantation 2 months later. 45 out of 47 patients felt that the surgery did have an impact on their social or professional life.

DISCUSSION

Gore-Tex (WL Gore and Associates, Flagstaff, Ariz) has been utilized as a biocompatible implant material since the early 1970s.³ Medical grade Gore-Tex is a semiporous implant material which allows for limited cascular ingrowth without significant inflammatory response. The report on the first series of cases of Gore-Tex medialization thyroplasty was presented at the Second International Symposium of Laryngeal and Tracheal Reconstruction at Monte Carlo, Monaco in May 1996 and the technique was first discussed in a review article by Hoffman and McCulloch in the same year.⁴

The flexibility of the Gore-Tex ribbon allows the surgeon to distribute the degree of medialization differentially along the length of the vocal fold, thus allowing finely tuned, intraoperative adjustments that do not involve removal and replacement of the entire prosthesis. The flexibility also allows the surgeon to fit the ribbon through a small cartilage fenestration. It also requires no carving, is relatively easy to place, and its malleability permits contouring of the surrounding tissue. Greater pliability decreases extrusion potential and makes Gore-Tex a more “natural” implant for vocal fold medialization.⁵

Some interesting observations can be made based on the analysis of our 47 patients who underwent Gore-Tex thyroplasty. First, video laryngoscopy demonstrated that 45 out of 47 patients had complete glottal closure. This can be interpreted to mean that patients who underwent Gore-Tex medialization thyroplasty were more likely to have closure after surgery than before the surgery. For maximal phonation time the trends were in the direction of improvement for all parameters studied. Patient satisfaction with voice improvement was almost universal and is statistically significant.

CONCLUSION

The authors have had good experience with the use of Gore-Tex thyroplasty. The technique has advantages over more

traditional prostheses. Gore-Tex is malleable, adjustable within the cartilaginous window, and requires only a small thyroplasty that can be created easily without disrupting the strap muscles. Video laryngoscopy, maximal phonation time and Patient’s self evaluation were in the direction of improvement for all parameters studied.

REFERENCES

1. Neel HB. Implants of ePTFE. *Arch Otolaryngol* 1983;109: 427-33.
2. Zeitels SM. Adduction arytenopexy with medialization laryngoplasty and cricothyroid sublaxation: A new approach to paralytic dysphonia. *Oper Techn Otolaryngol Head-Neck Surg* 1999;10:9-16.
3. McCulloch PM, Hoffman HT. Medialisation laryngoplasty with expanded polytetrafluoroethylene. Surgical technique and preliminary results. *Annals Otol Rhinol Laryngol* 1998;107: 427-32.
4. HT Hoffman, TM McCulloch. Anatomic considerations in the surgical treatment of unilateral laryngeal paralysis. *Head and Neck* 1996;18:174-87.
5. Zeitels SM, Mauri M, Dailey SH. Medialization laryngoplasty with Gore-Tex for voice restoration secondary to glottal incompetence: Indications and observations. *Ann Otol Rhinol Laryngol* Feb 2003;112(2):180-84.